

GLAUCOMA BASED DETECTION OF CUP TO DISC RATIO FROM RETINAL FUNDUS IMAGE: AN IMAGE PROCESSING TECHNIQUE

Anitha Duraisamy¹ and Suganthi M²

¹Research scholar, Anna university, Chennai, Tamilnadu, India. mail:assvanitha@gmail.com

²Professor, Mahendra College of Engineering, Salem, Tamil Nadu, India.

mail:msuganthib@gmail.com

*Corresponding mail: assvanitha@gmail.com

Abstract

This work proposes a method for the detection of glaucoma using fundus image based on the optic disc and cup size. The ratio of the optic cup to disc (CDR) in retinal fundus images is one of the primary physiological parameter for the diagnosis of glaucoma. Using SVM classifier the dataset is trained. The CDR values are considered as features for the prediction. Also, the advantages of using electrical stimulation for the treatment of glaucoma are proposed in this study. The mechanism underlying the electrical stimulation for the positive effects are outlined in connection with their effects on increased production of neurotrophic agents. Therefore through work, we aim to provide insight on the applications CDR and the advantages of electrical stimulation and its importance as a potential therapy for improving vision and treating various eye diseases.

Keywords: Glaucoma, fundus image, Cup to disc ratio. SVM classifier, Electrical Simulation.

Introduction

Glaucoma is a leading cause of irreversible blindness that occurs with progressive damage of optic nerve and retinal ganglion cells with concomitant visual field (VF) loss [1]. It is the second leading cause of blindness worldwide and in 2025 it is estimated that approximately 11 million individuals will be blind from glaucoma [2]. Currently, glaucoma can be treated. Glaucoma is considered as age-

related disease and the top most cause of permanent visual impairment [3]. The complications in glaucoma disease pathology have significantly suggested that its diagnosis is very important at its early stages to prevent the permanent visual loss [4]. This is a multifactorial ocular disease and is diagnosed by increased intra-ocular pressure (IOP), a crucial factor in the disease progression. The optic nerve head is distinguished as a brightest yellow oval

shape containing a central optic cup surrounded by an optic disc is seen in 2D images of retinal images (Figure.1)

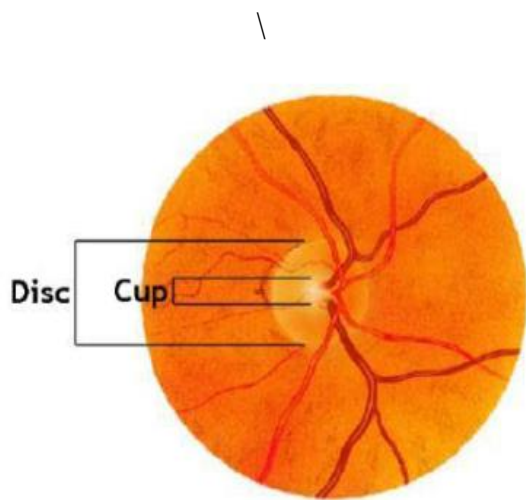


Figure 1. Optic cup and disc in retinal images

An increase in the IOP above the normal ranges (10-21 mmHg); create a pressure against optic nerves and leads to the degeneration of retinal ganglion cells [5]. However, the glaucomatous loss of visual field can be seen in some patients with normal IOP which significantly suggests that keeping low IOP alone is not enough to inhibit the glaucomatous optic neuropathy [6]. However, cup-disc ration (CDR) has become important in detection of glaucoma from the fundus image. The CDR value of 0.65 is considered to be suspicious for glaucoma [7]. This can be done by calculating the ratio of optic cup to disc area or ratio of cup-disc vertical diameter. However the physical detection and diagnosis of glaucoma is quite

laborious and depends on professional expertise. From the last few decades several Machine Learning techniques are used to prediction of glaucoma based on the fundus images [8]. Some of the techniques which have been used are neural networks, decision tree based on ID3 algorithms, Support Vector Machine, Naive Bayesian classifier, k- nearest neighbor, Thresholding, CDR and ISNT [9]. In this proposed work a novel algorithmic based based on Cup to Disc Ratio approach for the identification of glaucoma from fundus images was proposed.

Statement of Problem

An early detection of glaucoma is very crucial as it allows timely treatment to prevent major visual field loss. The diagnosis of glaucoma can be done through measurement of CDR (cup-to-disc ratio). Currently, CDR evaluation is very laborious and is performed manually by ophthalmologists. Thus, this paper proposes an intuitive, efficient and objective method for automatically classifying digital fundus images into either normal or glaucomatous types in order to facilitate ophthalmologists.

Methodology

In flowchart of proposed methodology for detection of glaucoma based on cup-to-disc ratio from fundus

images is shown in Figure 2. First step, pre-processing is intend to change of the picture for next investigation and processing. Here the image is resized to a color space changes and specific size in view of necessity. Second step, is segmentation procedure to concentrate on the Cup and Disc shapes from the input picture. Third is to measure the area of cup to disc ration of image and Finally trained with the SVM classifier.

ROI Determination

In this small portion of an image that was extracted and necessary operations are performed on it. ROI is defined as a binary image that has the same size as of the image we want to process. In the mask image, pixels which lie in ROI has been set to 1 and all other pixels has been set to 0. In retinal fundus image, the optic disc has been traced out as optic disc occupies less than 5% of pixels are extracted [10]. By localizing the ROI, it reduces the computational cost and also improves accuracy of segmentation .it is defined as a rectangle around the ROI centre with dimensions of twice the typical optic disc diameter, and has been used as the initial boundary for the optic disc segmentation.

Algorithm

Input: RGB fundus image

[1] Colored fundus image

[2] Region propping and Bounding box

[3] Crop the image in the bounded box

[4] Perform ISNT Mask Generation

[5] Extract the ROI of the image.

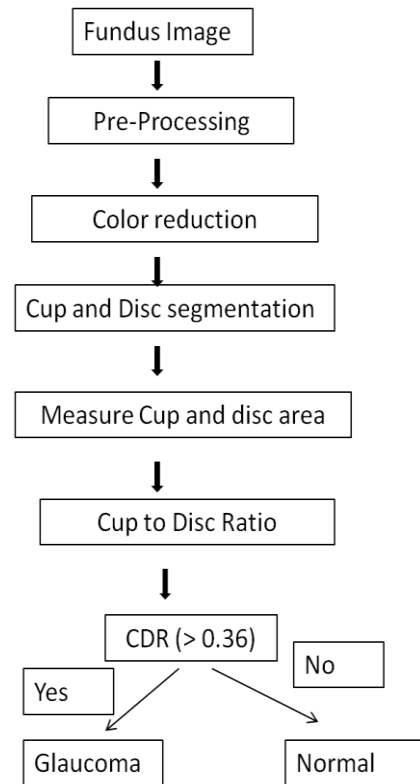


Figure. 2: Flow chart of this study

Optic Disc Segmentation and Smoothing

The disadvantages of Optic Nerve Head (ONH) will be eliminated by the segmentation process of optic disc and optic cup evaluation methods. For calculating the vertical cup to disc ratio firstly the optic cup and disc segmented from the retinal images [11]. There are various techniques for segmentation based on template matching, machine learning, active contour model, level sets and Hough transform. ellipse fitting has been applied in

order to reshape the disc boundary for smoothing.

Optic Cup Segmentation and Smoothing

Optic cup segmentation is bit harder than optic disc extraction since the cup-disc boundary is less measurable than that of disc region and besides combines with increased visibility of blood vessels across the cup-disc boundary. Ellipse fitting is an important tool especially when portions of the blood vessels in the neuro-retinal rim which is outside the cup are included within the detected boundary [12]. Based on the height of detected optic disc and cup, the cup to disc ratio (CDR) has been obtained.

Cup To Disc Ratio

The segmented cup and disc that consists of white pixels are counted to calculate the area of the cup and disc. Calculate the CDR and compare the ratio for normal cup to disc ratio. For normal eye CDR is 0.3, if the input image CDR exceeds more than 0.3, then it is to be considered as an image affected by glaucoma. If the Value is <0.36 the prediction is normal, If it is 0.36 and 0.5 Stage 1, 0.5 to 0.7 stage 2 and <0.7 stage 3 or advanced stage [13].

After finding normal or abnormality of fundus images (glaucoma), then SVM is used as classifier.

CDR is calculated as

$$\text{CDR} = (\text{Cup area} \div \text{Disc area}) \times 2 \dots (1)$$

Cross validation

In this study, normal fundus image and glaucoma are defined as positive and negative respectively. Therefore, TP stands for True Positives, TN - True Negatives, FP - False Positives and FN - False Negatives..

Sensitivity (Sn): sensitivity measures the ability of the process to predict correct results

$$\text{Sn} = \frac{\text{tp}}{\text{tp}+\text{fn}} \times 100\% \dots (2)$$

Specificity (Sp): specificity measures the ability of a process to predict incorrect results. ..

$$\text{Sp} = \frac{\text{tn}}{\text{tn}+\text{fp}} \times 100\% \dots (3)$$

Accuracy (Acc): accuracy measures the degree of correctness of the predicted results to its actual value or the experimental value

$$\text{Acc} = \frac{\text{tp}+\text{tn}}{\text{tp}+\text{fn}+\text{tn}+\text{fp}} \times 100\% \dots (4)$$

Results and Discussion

The cup to disc ratio (CDR) is an important indicator of the risk of the presence of glaucoma in an individual. The proposed algorithm is tested on 8 normal fundus images and 8 glaucoma fundus images. SVM classifier are used to analyze the performance of the proposed system. The noise handling, large dataset and large feature space abilities of SVM has put forth

its usage as a successful machine learning (ML)-technique [14]. SVM classification can separate the positive instances from negative instances with high margin. The parameters and kernels (linear, polynomial, radial base function (RBF) and sigmoid) were optimized for the best performance of SVM classifiers and trained with CDR as features. In statistical prediction, the jackknife cross-validation, also known as the Leave-One-Out Cross-Validation (LOOCV), is regarded as an objective and effective method to evaluate a classifier for its effectiveness in practical application. Thus a ten-fold cross-validation was used to evaluate the performance of SVM classifiers.

The SVM classifier was trained and optimized with CDR features. Various kernels such as linear, quadratic, polynomial, radial basis function (RBF), MLP and RBF_sigma were optimized for the best performance of the SVM classifiers. The kernel parameters (C and gamma) corresponding to maximum accuracy were optimized as best parameter values. The accuracy, sensitivity and specificity of normal fundus images were shown in figure.3. The AAC-SVM classifier optimized with RBF kernel has the highest accuracy of 79.13% followed by Polynomial kernel with 78.54%. The lowest accuracy of 52.38 % was exhibited by MLP

kernel. The average accuracy was considered for the best performance of a kernel. Thus in the present study, RBF kernel was considered as the most suitable kernel for the SVM classifiers-training and testing with normal fundus image features.

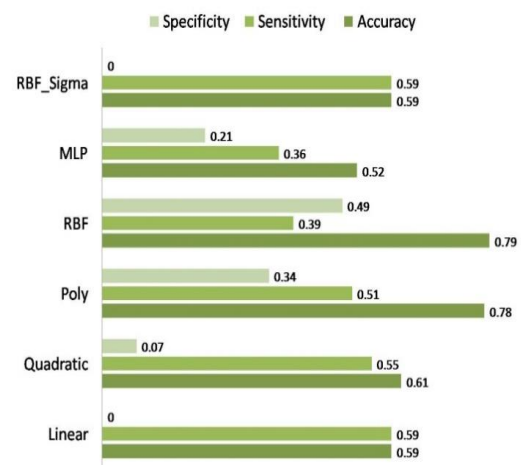


Figure.3: The performance evaluation of SVM classifier for CDR with various kernels

Cup to disc ratio of normal and abnormal images

To find the disc area of input image with different threshold values are applied and related to the cup areas. After finding disc area keep disc area as constant for all the different images of the eye and cup area varied by applying threshold values for different regions. In the present technique the author measures the cup area and disc area keeping the structuring element on it and do the segmentation for required region, which gives the more accurate result compare to previous result

The normal cup to disc ratio is 0.3. The increase in cup ratio may imply glaucoma or other pathology. The cup-to-disc ratio compares the diameter of the "cup" portion of the optic disc with the total diameter of the optic disc. The cup-to-disc ratio of normal subjects is typically around 0.2 to 0.3. While there is no one cup-to-disc ratio that separates normal from glaucoma, the cup-to-disc ratio greater than 0.6 or 0.7 is suspicious of glaucoma and often requires further testing to rule out glaucoma.

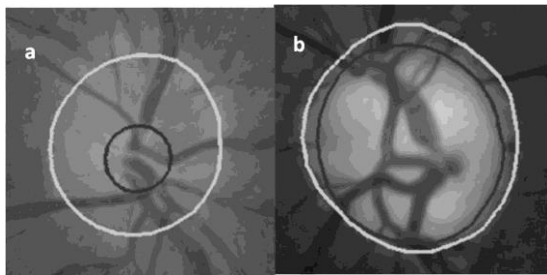


Figure4: cup to disc ratio fundus retinal images (a) normal (CDR<0.36) (b) glaucoma (CDR >0.36)

Table. 1: Prediction of SVM classifier of Normal and Glaucoma fundus images based on CDR

S.no	CDR	Prediction
1.	0.328	Normal
2.	0.38	Glaucoma
3.	0.304	Normal

4.	0.410	Glaucoma
5.	0.319	Normal
6.	0.329	Normal
7.	0.443	Glaucoma
8.	0.216	Normal
9.	0.169	Normal
10.	0.498	Glaucoma
11.	0.392	Glaucoma
12.	0.216	Normal
13.	0.501	Glaucoma
14.	0.455	Glaucoma
15.	0.272	Normal
16.	0.389	Glaucoma

Currently, to treat and improve the patients' vision, the electrical stimulations are being applied as epiretinal, subretinal, transchoroidal, transcorneal, transorbital, transpalpebral and direct stimulation of brain or eye. In early methods that are simple to implement and non invasive, the electrical stimulations targets retinal cells alone, while direct method targets higher visual cells. In advanced glaucoma patients, where the connections between the eye and brain are affected, the later direct method that stimulates the brain is very useful therapeutic strategy.

The methods such as epiretinal, subretinal, transchoroidal electrical stimulations are known as retinal implants or chips or prostheses. These retinal prostheses mimic photoreceptor activities by using electricity generated by energy converters. The ganglion cells are targeted by epiretinal prostheses and inner nuclear layer of the retina are targeted by subretinal implants while transchoroidal implants stimulate the retina from the outer region. In retinal pigmentosa patients, the defective pigment epithelium and photoreceptors are observed while the inner retina and ganglion cell layer are kept intact. The retinal prostheses must activate the retinal neurons by detecting the light when converting light energy into electricity in order to restore the visual function.

Conclusions

In this study, we have presented a method to calculate the CDR automatically from fundus images. First step, pre-processing is intend to change of the picture for next investigation and processing. Here the image is resized to a color space changes and specific size in view of necessity. Second step, is segmentation procedure to concentrate on the Cup and Disc shapes from the input picture. Third is to measure the area of cup to disc ration of image and Finally trained with the SVM classifier.. Using 16 images the

performance of our approach is evaluated using SVM. The results indicate that our approach provides 89% accuracy in glaucoma analysis. Conversely, this study has a good potential in automated screening systems for the early detection of glaucoma based on CDR. In this scenario, currently the usage of electrical stimulation for the treatment of glaucoma and vision restoration has moved into clinical practice. Its favorable safety profile is key advantage and is likely to boost the progress of electrical stimulation in the treatment of various eye diseases. However, there is a urgent need for a deeper understanding of the underlying mechanisms of this electrical stimulations restoring the vision.

References

- [1] Cheng JW, Cheng SW, Ma XY, Cai JP, Li Y, Lu GC, Wei RL. Myocilin polymorphisms and primary open-angle glaucoma: A systematic review and meta-analysis. *PloS one*. 2012; 7: e46632.
- [2] Quigley HA, Broman AT. The number of people with glaucoma worldwide in 2010 and 2020. *Br. J. Ophthalmol*. 2006; 90: 262–267.
- [3] Coleman AL, Miglior S. Risk factors for glaucoma onset and progression. *Surv. Ophthalmol*. 2008; 53: S3–10.
- [4] Wang SK, Chang RT. An emerging treatment option for glaucoma: Rho kinase

inhibitors. *Clin. Ophthalmol.* 2014; 8: 883–890.

[5] Tang M, Fu Y, Fan Y, Fu MS, Zheng Z, Xu X. In-silico design of novel myocilin inhibitors for glaucoma therapy. *Trop. J. Pharm. Res.* 2017;16: 2527-2533.

[6] Chen J, Runyan SA, Robinson MR. Novel ocular antihypertensive compounds in clinical trials. *Clin. Ophthalmol.* 2011; 5: 667–677.

[7] R. Chrastek a, M. Wolf a, K. Donath, “Automated segmentation of the optic nerve Medical Image Analysis in Elsevier, Functional Imaging and Modeling of the Heart, August 2005, pp 297-314.

[8] Ahmed Wasif Reza & C. Eswaran & Subhas Hati, “Automatic Tracing of Optic Disc and Exudates from Color Fundus Images Using Fixed and Variable Thresholds”, *Journal of Medical Systems*, Feb 2009, pp 73 -80.

[9] J. Liu, D. W. K. Wong, J.H. Lim, X. Jia, “Optic Cup and Disk Extraction from Retinal Fundus Images for Determination of Cup-to-Disc Ratio”, *IEEE third conference on Industrial Electronics and Applications*, June 2008, pp 1828 -1832.

[10] Koen A. Vermeer, Frans M. Vos, Barrick Lo, *Images of the Human Retina for Progression Detection of Glaucoma*”, *IEEE Transactions On Medical Imaging*, May 2006, pp 517-528.

[11] T. Walter and J. C. Klein, “Automatic analysis of color fundus photographs and its application to the diagnosis of diabetic retinopathy,” in *Handbook of Biomedical Image Analysis*, vol. 2, pp. 315-368, 2005.

[12] Prasad Maladhure, N. and Dixit, V. V. *Glaucoma Detection Using Optic Cup and Optic*

Disc Segmentation. International Journal of Engineering Trends and Technology, **20(2)**,

2015, pp. 52-55.

[13] Ann mary babu and Hanis, S. *Segmentation of optic disc boundary in digital Fundus images.*

International journal of biomedical signal processing, **2(1)**, 2012, pp. 1-6.

[14] U. Rajendra Acharya, Sumeet Dua, Xian Du, “Automated Diagnosis of Glaucoma Using Texture and Higher Order Spectra Features”, *IEEE Transactions On Information Technology In Biomedicine*, May 2011, pp 449-455.